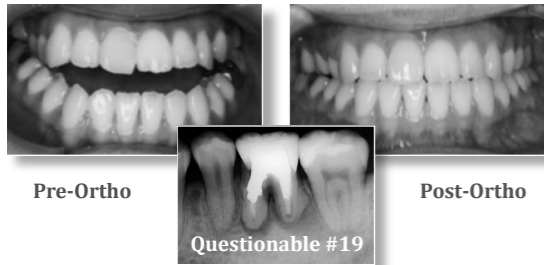

CRYOPRESERVATION

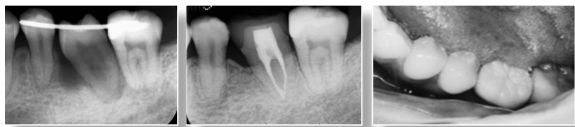If the idea of moving a tooth from one place in the mouth to another wasn't science fiction enough, just imagine extracting your tooth, freezing it for several years, and thawing it out to transplant it in your mouth in the future when you need it.

This technique is a reality. In order to avoid the normal destruction of the cell structures by sharp ice crystals, a very specific, slow, deep freezing process is used.

The teeth can be frozen indefinitely and have been shown to function just the same as natural teeth once transplanted as illustrated in the case below. This 24 year old patient had a class III occlusion with open bite. At the time of orthognathic surgery to advance the maxilla 5mm and retract the mandible 5mm, the maxillary first premolars were extracted and cryopreserved for eventual replacement of questionable tooth #19.



Six years after cryopreservation, the premolar was thawed out to replace tooth #19. It was endodontically treated and restored to look like a molar with stability at 3 years post restoration.



Angle Orthodontist. Kaku et al, 2015



Copyright 2016 Dr. Pamela Nicoara

WHAT IS AUTOTRANSPLANTATION?

As mentioned in the February newsletter, tooth autotransplantation is the surgical extraction of a tooth from one location in the alveolus, with implantation at a different position in the ridge.

When I first reported on this, I was only aware of autotransplantation of immature teeth. This was, in fact, how the original procedure was designed to be used by Bjercke and Slagsvold in 1959. Indeed, the majority of the Scandinavian literature reports on the use of immature teeth. However, after a trip to Poland in May to participate in the First Congress on Tooth Autotransplantation, our Asian colleagues showed that this technique has been very successfully used on fully developed teeth in adult patients. This opens up a much greater scope for the use of this extraordinary option for tooth replacement.

At the Congress in Poland, I had the great honor to meet Dr. Dick Barendregt who performs autotransplantation on a daily basis. He allowed me to observe him for 7 days in his clinic in Rotterdam treating young and old alike, so that I would be prepared to perform this technique for your patients.

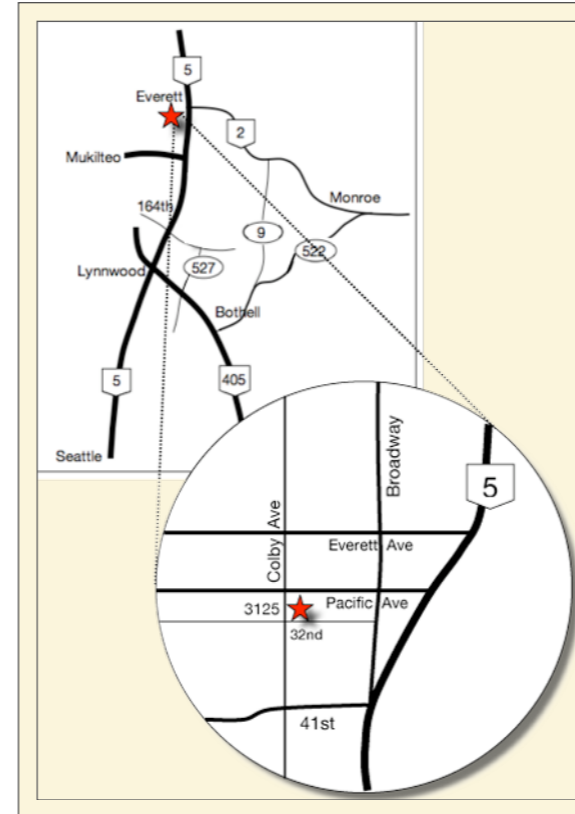
With 98% success rates similar to implants, and up to 41 years of successful follow up, autotransplantation is just the first step in the march towards implanting teeth rather than titanium.  

Transplantation of teeth #12 (and 4) to #20 (and 29). Courtesy of Dr. Dick Barendregt

This issue of **ProbeTips** will demonstrate situations where autotransplantation can be utilized for mature teeth.

Pamela A Nicoara DDS MSD PLLC

PERIODONTOLOGY IMPLANTOLOGY ORAL MEDICINE



3125 Colby Avenue, Suite H
Everett WA 98201

T: 425-374-5380 F: 425-374-5382

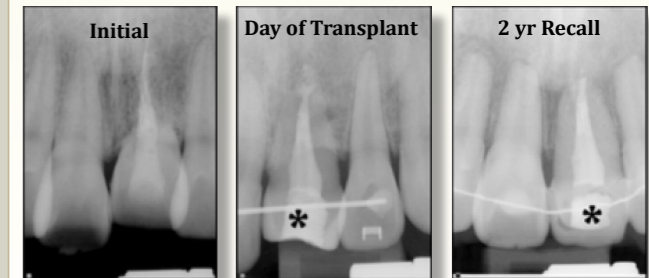
www.NICOARaperio.com
doctor@NICOARaperio.com

PROBE TIPS

A QUARTERLY PERIODONTAL
NEWSLETTER

BY PAMELA NICOARA DDS MSD

Autotransplantation of Mature Teeth



AJODO. Choi et al, 2014

VOLUME 9, No. 3

NOVEMBER 2016

Autotransplantation of Mature Teeth

GENERAL CONSIDERATIONS

Unlike an immature tooth with an open apex which has the potential to finish forming the root once transplanted, a fully formed tooth when extracted will lose innervation to the pulp and require root canal therapy. As long as the PDL is not damaged during extraction, the tooth will behave just like an orthodontically moved tooth and should heal without ankylosis or resorption.

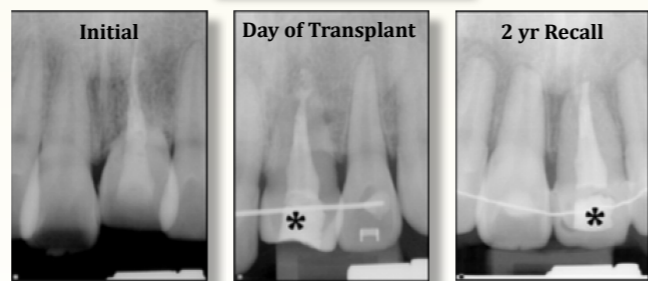
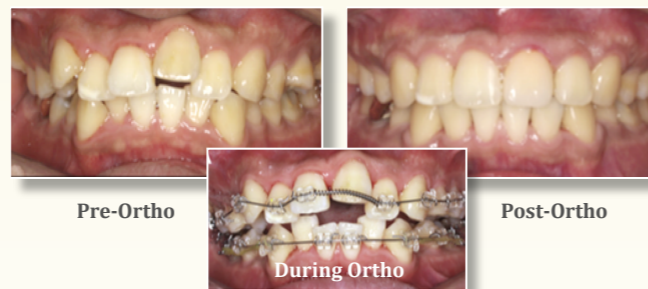The uses of an immature tooth to replace a missing or failing tooth as shown in the prior newsletter are no different from the situations in which you can use a fully mature endodontically treated tooth. Premolars can be moved to other premolar sites, to molar sites, or to central incisor sites. Molars can be moved to other molar sites, and if they are small enough, even to lateral incisor positions. The recipient site can be a fresh extraction socket, or an edentulous ridge. However, research has indicated that the longer a site has been edentulous, the less successful the transplant will be.

COORDINATION AMONGST PRACTITIONERS

As you have seen so far, orthodontic treatment is an integral part of the autotransplantation process. Careful coordination and treatment planning with the orthodontist is paramount in obtaining the right result. Will the patient have any detriment to their facial profile if premolars are removed and space is closed? What if this is done unilaterally? Will temporary anchorage devices be necessary? Will space be maintained for an implant in a less esthetic and less surgically and technically demanding

site? Will the tooth be positioned in the correct location in the ridge for the best esthetic outcome?

It is also very important to coordinate care with the restorative dentist. When the transplant is replacing a tooth other than its own kind (ex: a premolar replacing a central), the transplant must be restored to look like the tooth it is replacing. This must be done ideally prior to the start of orthodontic treatment, and in line with the long axis of the transplant, even if it is poorly inclined. This will allow the orthodontist can place the bracket in the ideal location for the best outcome to prevent loss of papilla or facial recession which can happen if the tooth is too far facial. The case below shows replacement of failing tooth #9 with of one of the 4 premolars removed for orthodontic purposes.



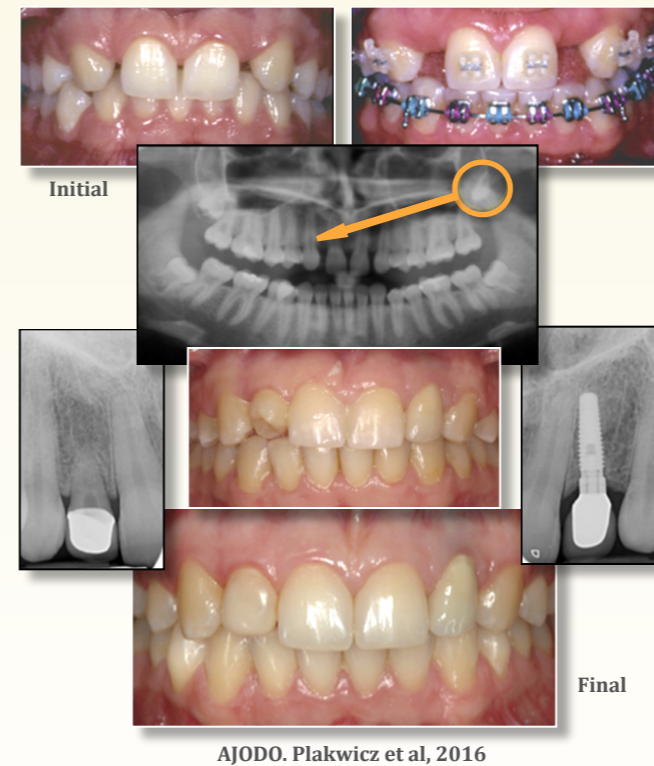
AJODO. Choi et al, 2014

Six weeks or more after transplantation, the orthodontist can position the premolar to level the CEJ with the adjacent central, or in this case, rotate the tooth to match the width of the adjacent tooth.

LONG TERM OUTCOMES

One very interesting paper has made it very clear that although titanium implants have been the best we can offer for tooth replacement, its hard to beat having your own natural tooth.

This patient was congenitally missing her maxillary lateral incisors. Her immature maxillary left 3rd molar was small enough to use as a lateral incisor to replace tooth #7. Site #10 was restored with an implant.



There is a grey shadow in the soft tissues over the implant, and the implant crown is longer than the crown on #7. Adding connective tissue can improve this, but for how long? The natural tooth will never have this problem.

CONCLUSIONS

I'm so pleased to be able to share with you a treatment option like no other.

- We can help a young child avoid years of difficult space maintenance of a lost upper central incisor during growth while waiting for a titanium tooth replacement. How many surgeries would it take to rebuild a ridge to less than ideal outcomes, which will never get better as they age?
- We can rebuild bone in a cleft palate area by transplanting a developing tooth into the missing bone. How many ridge augmentation surgeries does it take to get as close to natural as autotransplantation does?
- We can reduce orthodontic treatment time by multiple years when we can surgically upright a completely horizontal canine.
- We can replace congenitally missing premolars with teeth from the opposite arch, close spaces, and avoid titanium implants.
- Just think how many wisdom teeth are extracted that are in good positions that can be maintained for future use!

Its a new way of thinking for many of us, but it is worth thinking about! I place implants nearly every day. If I had a choice and I had a tooth available with the opportunity to orthodontically close space, I'd much rather have a natural tooth over an implant.

REFERENCES

- Dental Press J Orthod.* Tanne, K. 2014.
AJODO. Choi YJ et al. 2014.
Angle Orthod. Kaku, M et al. 2015.
AJODO. Plakwicz P et al. 2016.

Complete references available on request.